

Rapporteurs:

Alexandre Hurtgen and Sina Esfandiari,
with Isabelle Laleman and Prof. France Lambert

Affiliation:

Postgraduate programme in periodontology,
University of Liège, Belgium

study

Immediate implants: effect of soft-tissue augmentation on tissue preservation

Authors:

Chun-Teh Lee, Duong Tran, Yosuke Tsukiboshi, Seiko Min, Sung K. Kim, Srinivas Ayilavarapu, Robin Weltman

Background

Immediate implant placement was suggested as an alternative to delayed implant placement back in the 1970s, and it has become clear that immediate implants show high survival rates and stable interproximal-bone levels. The advantages of this technique compared to delayed implant placement include fewer clinical visits, fewer surgical interventions, less post-operative morbidity, and – in some cases – the possibility of immediate loading.

However, even with immediate implantation, hard- and soft-tissue remodelling can be expected, which can lead to challenges in the aesthetic area. To reduce these dimensional changes – which can potentially result in mucosal recession – various soft- and hard-tissue augmentation procedures have been suggested.

At present, the evidence on soft-tissue augmentation around immediate implants is rather scarce, especially regarding the use of acellular dermal matrices.

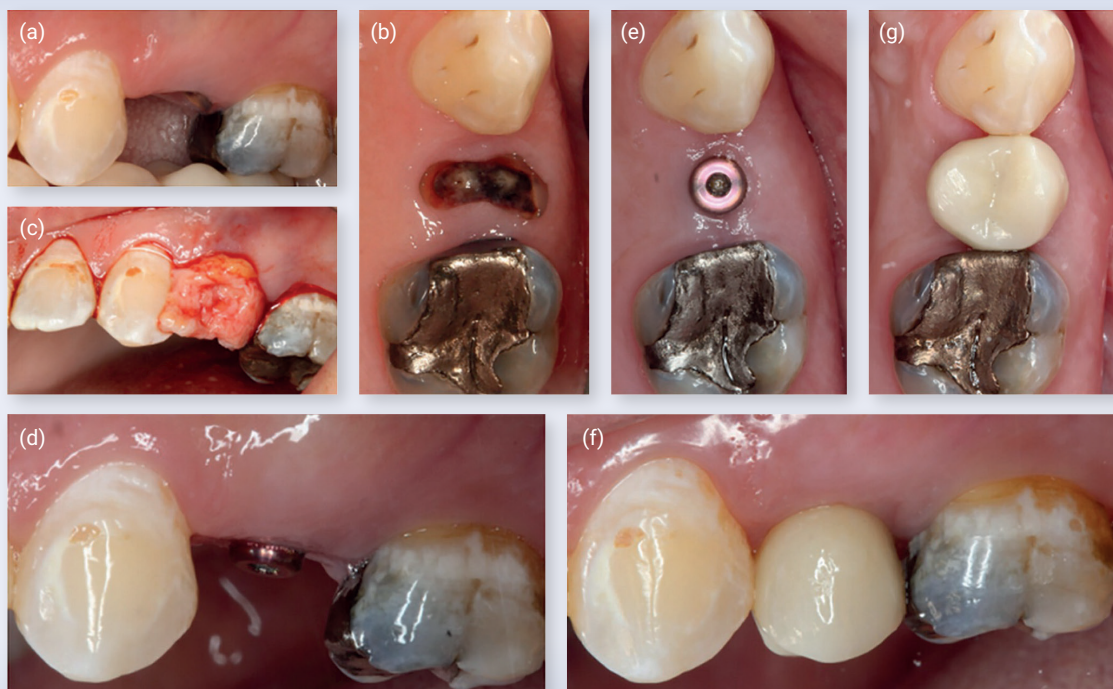Aim

To evaluate the effect of a sub-epithelial connective tissue graft (SCTG) or an acellular dermal matrix (ADM) versus no soft-tissue augmentation (NSTA) on tissue alterations around immediate implants in the anterior maxilla, based on a randomised controlled trial, with a one-year follow-up.

Materials & methods

- Systemically healthy patients in need of an extraction in the anterior maxilla (incisor, canine, or premolar region) not caused by periodontal disease.
- Teeth were free of gingival recessions ≥ 2 mm and with at least 3mm keratinised tissue width.
- Immediate implant placement was possible.
- Sample-size calculation was based on soft-tissue contour alterations after six months.
- To detect 1mm difference with standard deviation (SD) of 0.85 and an 80% power, 11 participants per group were needed.
- After allowing for dropouts: 15 participants per group were included, and were then randomised into three groups:
 - Immediate implant placement with SCTG.
 - Immediate implant placement with ADM.
 - Control group: immediate implant without any soft-tissue augmentation (NSTA).
- Platform-switched implants were placed flapless and 1mm below the mid-buccal crestal level:
 - SCTG group: partial-thickness pouch and SCTG harvested from palate.
 - ADM group: partial-thickness pouch and ADM provided by the manufacturer.
 - NSTA group: no soft-tissue augmentation.
- Final implant restoration was placed after six months.
- Study appointments: initial consultation, implant surgery, two weeks, one month, two months, three months, six months, and 12 months.
- Measurements of interest:
 1. Pocket depth (PD), bleeding on probing (BoP), and plaque level (PL) measured at six sites per tooth.
 2. Peri-implant mucosal level (based on prefabricated stent).
 3. Keratinised-tissue width.
 4. Buccal soft-tissue thickness.
 5. Buccal soft-tissue contour of the implant site.
 6. Marginal-bone level based on standardised periodical radiographs.
 7. Patient-reported outcomes (satisfaction with the implant procedure and outcomes).

Figure: Immediate implant with subepithelial connective-tissue graft group (SCTG group)



Note: (a) pre-surgical clinical photograph, buccal view; (b) pre-surgical clinical photograph, occlusal view; (c) placement of a subepithelial connective-tissue graft; (d) six-month clinical photograph, buccal view; (e) six-month clinical photograph, occlusal view; (f) 12-month clinical photograph, buccal view; (g) 12-month clinical photograph, occlusal view.

Results


- 46 patients in three groups:
 - SCTG group: 15 - ADM group: 15 - NSTA (control) group: 16
- After 12 months:
 - Mean buccal recession was $\leq 1\text{mm}$ in all three groups, with no statistical differences among the three groups.
 - Average recession depth was deepest in the ADM group and shallowest in the SCTG group.
 - The prevalence of recession $>1\text{mm}$ was 7.14% in the SCTG group, 20% in the ADM group, and 7.14% in the control group.
 - The mean keratinised tissue width was slightly decreased compared with baseline in all groups, without any statistically significant difference between them.
- Peri-implant mucosal thickness was greater in the SCTG and ADM groups than in the control group, with no significant differences between SCTG and ADM.
- Buccal contour reductions were significantly greater in the control group than the SCTG and ADM groups. Multivariate analysis showed a protective effect of the SCTG procedure and better outcome in premolars.
- Mean marginal bone loss never exceeded 1.5mm, with no statistical differences between the three groups.
- Patient satisfaction was very high in all three groups, with no statistical differences between the three groups.
- The soft-tissue augmentation procedure did not lead to more complications.

Limitations

- The examiner supervised the placement of the implants and therefore was not blinded.
- Surgeries were carried out by 18 different practitioners, and it seems difficult to calibrate such a large number of practitioners.
- Linear analysis of the soft tissue does not represent three-dimensional volumetric changes.
- There was no evaluation of aesthetics, for example by using the pink aesthetic score or the white aesthetic score.
- The follow-up period was limited to only one year, and it would have been interesting to have had longer follow-up results.

Conclusions & impact

- It is possible to maintain the soft-tissue contour and increase the soft-tissue thickness by means of a soft-tissue augmentation procedure at immediate implant sites.
- However, peri-implant mucosal recession or interproximal bone resorption cannot be prevented through soft-tissue augmentation.
- A trend for more stable soft-tissue outcomes could be observed for the SCTG group compared to the ADM group, but this was not statistically significant.
- This study suggests the importance of soft-tissue augmentation procedures during immediate implant placement and proves there are different ways to maintain the soft-tissue contours.

 JCP Digest 115 is a summary of "Clinical efficacy of soft tissue augmentation on tissue preservation at immediate implant sites: A randomised clinical trial." *J Clin Periodontol.* 2023; 50(7):1010-1020. DOI: 10.1111/jcpe.13816

 <https://www.onlinelibrary.wiley.com/doi/10.1111/jcpe.13816>

 Access through EFP members' page log-in: <http://efp.org/members/jcp.php>